2ª Jornada Sobre Cáncer de Pulmón y Oncología Torácica del País Vasco

Actualización en el Manejo Multidisciplinar del CPNM Localizado/localmente Avanzado

ESTADIFICACION DEL MEDIASTINO (RETO Y DESAFIO)

Juan C. Santana Astudillo

Servicio de broncoscopias H.U.D.

Bilbao 08/04/2025

The International Association for the Study of Lung Cancer Lung Cancer Staging Project: Proposals for Revision of the TNM Stage Groups in the Forthcoming (Ninth) Edition of the TNM Classification for Lung Cancer

Check for updates

Ramón Rami-Porta, MD,[a,b,*] Katherine K. Nishimura, PhD, MPH,[c] Dorothy J. Giroux, MS,[c] Frank Detterbeck, MD,[d] Giuseppe Cardillo, FRCS, FETCS,[e,f] John G. Edwards, PhD, FRCS(C/Th),[g] Kwun M. Fong, MD, M.B.B.S., FRACP,[h] Meredith Giuliani, M.B.B.S.,[i] James Huang, MD,[j] Kemp H. Kernstine Sr., MD, PhD,[k] Edith M. Marom, MD,[l] Andrew G. Nicholson, DM, FRCPath.,[m] Paul E. Van Schil, MD,[n] William D. Travis, MD,[o] Ming S. Tsao, MD,[p] Shun-Ichi Watanabe, MD,[q] Valerie W. Rusch, MD,[r] Hisao Asamura, MD[s]; Members of the IASLC Staging and Prognostic Factors Committee and of the Advisory Boards, and Participating Institutions[t]

[a]*Department of Thoracic Surgery, Hospital Universitari Mutua Terrassa, University of Barcelona, Terrassa, Barcelona, Spain*
[b]*Network of Centers for Biomedical Research in Respiratory Diseases (CIBERES) Lung Cancer Group, Terrassa, Barcelona, Spain*
[c]*Cancer Research And Biostatistics (CRAB), Seattle, Washington*
[d]*Department of Surgery, Yale University, New Haven, Connecticut*
[e]*Department of Thoracic Surgery, Azienda Ospedaliera San Camillo-Forlanini, Rome, Italy*
[f]*UniCamillus-Saint Camillus International University of Health Science, Rome, Italy*
[g]*Department of Cardiothoracic Surgery, Sheffield Teaching Hospitals NHS Foundation Trust, Northern General Hospital, Sheffield, United Kingdom*
[h]*Department of Thoracic Medicine, University of Queensland Thoracic Research Centre, The Prince Charles Hospital, Chermside, Brisbane, Queensland, Australia*
[i]*Princess Margaret Cancer Centre, University Health Network, Toronto, Ontario, Canada*
[j]*Thoracic Service, Department of Surgery, Memorial Sloan Kettering Cancer Center, New York, New York*
[k]*Cardiovascular and Thoracic Surgery, University of Texas Southwestern, Dallas, Texas*
[l]*The Chaim Sheba Medical Center, University of Tel Aviv, Tel Aviv, Israel*
[m]*Department of Histopathology, Royal Brompton and Harefield NHS Hospitals, Guy's and St. Thomas' NHS Foundation Trust and National Heart and Lung Institute, Imperial College, London, United Kingdom*
[n]*Department of Thoracic and Vascular Surgery, Antwerp University Hospital and Antwerp University, Edegem (Antwerp), Belgium*
[o]*Department of Pathology, Memorial Sloan Kettering Cancer Center, New York, New York*
[p]*Department of Pathology, Princess Margaret Cancer Centre, Toronto, Ontario, Canada*
[q]*Division of Thoracic Surgery, National Cancer Center Hospital, Tokyo, Japan*
[r]*Department of Surgery, Memorial Sloan-Kettering Cancer Center, New York, New York*
[s]*Division of Thoracic Surgery, Keio University School of Medicine, Tokyo, Japan*

Received 4 January 2024; revised 22 February 2024; accepted 27 February 2024
Available online - 4 March 2024

Table 2. Proposed T, N, and M Categories and Descriptors for the Ninth Edition of the TNM Classification for Lung Cancer

T: Primary tumor	
Tx	Primary tumor cannot be assessed[a]
T0	No evidence of primary tumor
Tis	Carcinoma in situ[b]
T1	Tumor surrounded by lung or visceral pleura or in a lobar or more peripheral bronchus[c]
T1mi	Minimally invasive adenocarcinoma[d]
T1a	Tumor ≤1 cm in greatest dimension
T1b	Tumor >1 cm but ≤2 cm in greatest dimension
T1c	Tumor >2 cm but ≤3 cm in greatest dimension
T2	Tumor with any of the following features:
T2a	Tumor >3 cm but ≤4 cm in greatest dimension invades visceral pleura invades an adjacent lobe involves main bronchus (up to but not including the carina) or is associated with atelectasis or obstructive pneumonitis, extending to the hilar region, involving either part of or the entire lung
T2b	Tumor >4 cm but ≤5 cm in greatest dimension
T3	Tumor with any of the following features: tumor >5 cm but ≤7 cm in greatest dimension invades parietal pleura or chest wall invades pericardium, phrenic nerve, or azygos vein[e] invades thoracic nerve roots (i.e., T1, T2) or stellate ganglion separate tumor nodule(s) in the same lobe as the primary
T4	Tumor with any of the following features: tumor >7 cm in greatest dimension invades mediastinum, thymus, trachea, carina, recurrent laryngeal nerve, vagus nerve, esophagus, or diaphragm invades heart, great vessels (aorta, superior or inferior vena cava, intrapericardial pulmonary arteries or veins), supra-aortic arteries, or brachiocephalic veins invades subclavian vessels, vertebral body, lamina, spinal canal, cervical nerve roots, or brachial plexus (i.e., trunks, divisions, cords, or terminal nerves) separate tumor nodule(s) in a different ipsilateral lobe than that of the primary
N: Regional lymph node involvement	
Nx	Regional lymph nodes cannot be assessed
N0	No regional lymph node metastasis
N1	Metastasis in ipsilateral peribronchial or ipsilateral hilar or intrapulmonary lymph nodes, including involvement by direct extension
N2	Metastasis in ipsilateral mediastinal or subcarinal lymph node(s)
N2a	Metastasis(es) in a single ipsilateral mediastinal or in the subcarinal nodal station
N2b	Metastases in multiple ipsilateral mediastinal nodal stations with or without involvement of the subcarinal nodal station
N3	Metastasis in contralateral mediastinal, contralateral hilar, ipsilateral or contralateral scalene or supraclavicular lymph node(s)
M: Distant metastasis	
M0	No distant metastasis
M1	Distant metastasis
M1a	Tumor with pleural or pericardial nodules or malignant pleural or pericardial effusions,[f] separate tumor nodule(s) in a contralateral lobe
M1b	Single extrathoracic metastasis in a single organ system[g]
M1c	Multiple extrathoracic metastases in a single or multiple organ system(s)
M1c1	Multiple extrathoracic metastases in a single organ system[h]
M1c2	Multiple extrathoracic metastasis in multiple organ systems

1014 Rami-Porta et al Journal of Thoracic Oncology Vol. 19 No. 7

8th Ed TNM Categories

8th Ed TNM Categories					
T/M	Label	N0	N1	N2	N3
T1	T1a	IA1	IIB	IIIA	IIIB
	T1b	IA2	IIB	IIIA	IIIB
	T1c	IA3	IIB	IIIA	IIIB
T2	T2a Inv	IB	IIB	IIIA	IIIB
	T2a >3-4	IB	IIB	IIIA	IIIB
	T2b >4-5	IIA	IIB	IIIA	IIIB
T3	T3 >5-7	IIB	IIIA	IIIB	IIIC
	T3 Inv	IIB	IIIA	IIIB	IIIC
	T3 Same Lobe Nod	IIB	IIIA	IIIB	IIIC
T4	T4 >7	IIIA	IIIA	IIIB	IIIC
	T4 Inv	IIIA	IIIA	IIIB	IIIC
	T4 Ipsi Nod	IIIA	IIIA	IIIB	IIIC
M1	M1a Pl Dissem	IVA	IVA	IVA	IVA
	M1a Contr Nod	IVA	IVA	IVA	IVA
	M1b Single Les	IVA	IVA	IVA	IVA
	M1c Mult Les	IVB	IVB	IVB	IVB

Proposed 9th Ed TNM Categories

Proposed 9th Ed TNM Categories						
T/M	Description	N0	N1	N2		N3
				N2a	N2b	
T1	T1a ≤1 cm	IA1	IIA	IIB	IIIA	IIIB
	T1b >1 to ≤2 cm	IA2	IIA	IIB	IIIA	IIIB
	T1c >2 to ≤3 cm	IA3	IIA	IIB	IIIA	IIIB
T2	T2a Visceral pleura / central invasion	IB	IIB	IIIA	IIIB	IIIB
	T2a >3 to ≤4 cm	IB	IIB	IIIA	IIIB	IIIB
	T2b >4 to ≤5 cm	IIA	IIB	IIIA	IIIB	IIIB
T3	T3 >5 to ≤7 cm	IIB	IIIA	IIIA	IIIB	IIIC
	T3 Invasion	IIB	IIIA	IIIA	IIIB	IIIC
	T3 Same lobe tumor nodule	IIB	IIIA	IIIA	IIIB	IIIC
T4	T4 >7 cm	IIIA	IIIA	IIIB	IIIB	IIIC
	T4 Invasion	IIIA	IIIA	IIIB	IIIB	IIIC
	T4 Ipsilateral tumor nodule	IIIA	IIIA	IIIB	IIIB	IIIC
M1	M1a Pleural / pericardial dissemination	IVA	IVA	IVA	IVA	IVA
	M1a Contralateral tumor nodule	IVA	IVA	IVA	IVA	IVA
	M1b Single extrathoracic lesion	IVA	IVA	IVA	IVA	IVA
	M1c1 Multiple lesions, 1 organ system	IVB	IVB	IVB	IVB	IVB
	M1c2 Multiple lesions, >1 organ system	IVB	IVB	IVB	IVB	IVB

Figure 2. Proposed ninth edition TNM stage groups. Mult, multiple.

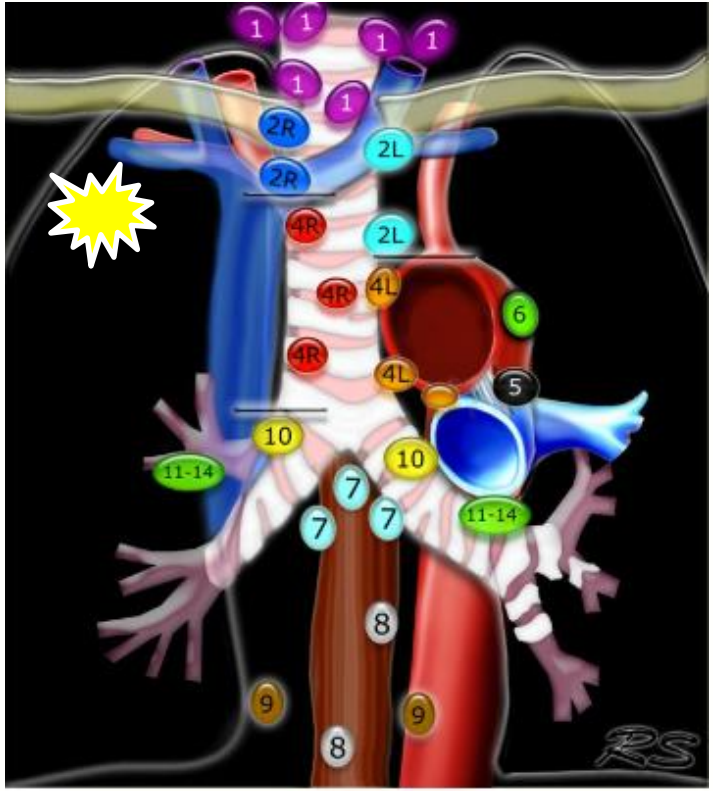

¿ Que es lo que pide de esta prueba el comité de tumores o el especialista que lo solicita?

Siempre necesitamos ver las imágenes del TAC y PET-TAC

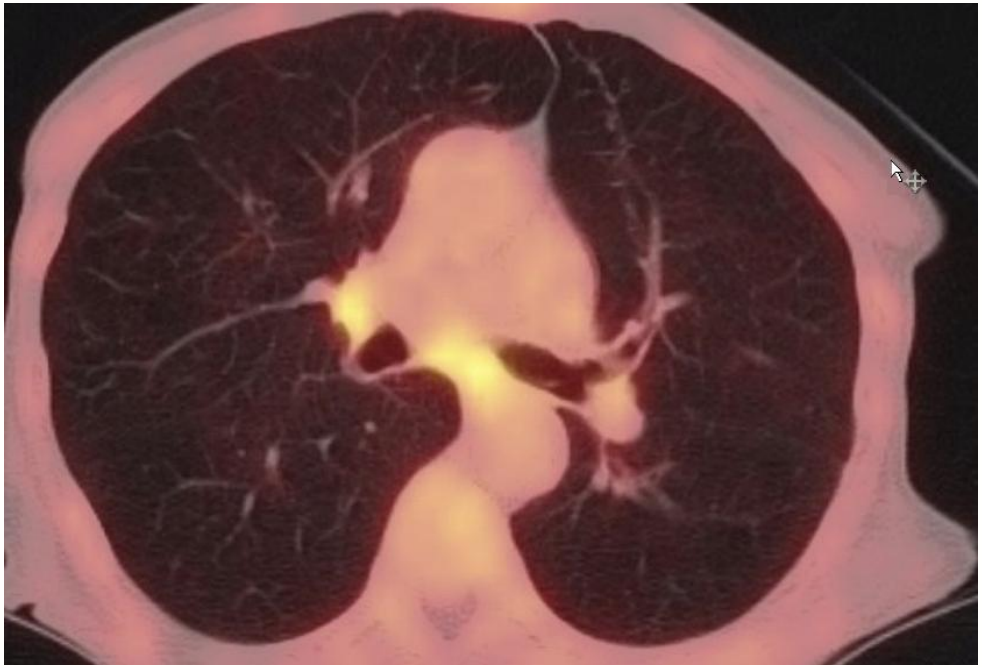

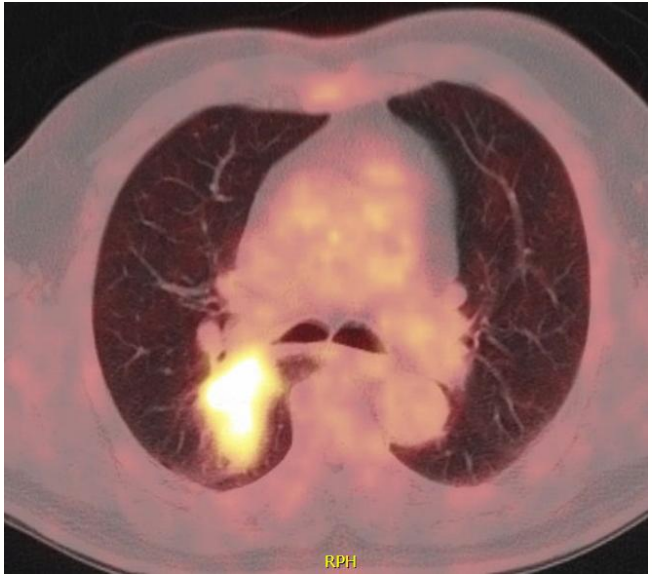
RPH

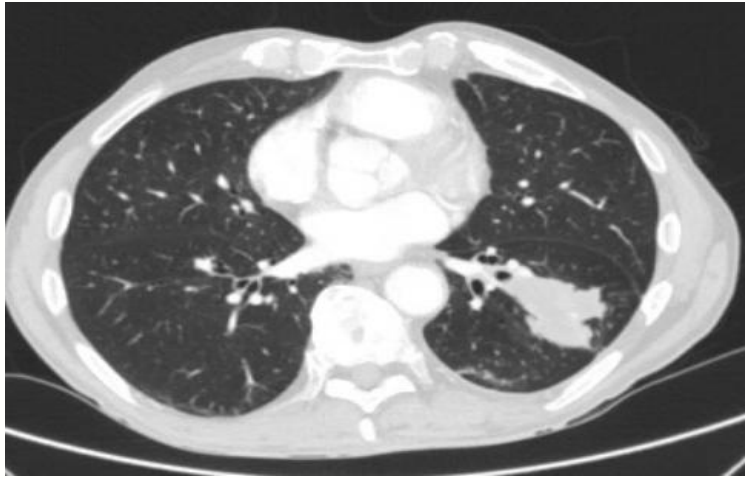

Huang et al. BMC Pulmonary Medicine (2021) 21:423
https://doi.org/10.1186/s12890-021-01748-4

BMC Pulmonary Medicine

RESEARCH Open Access

Diagnostic value of endobronchial ultrasound elastography combined with rapid onsite cytological evaluation in endobronchial ultrasound-guided transbronchial needle aspiration

Jing Huang[1], Yuan Lu[1], Xihua Wang[1], Xiaoli Zhu[1], Ping Li[1], Jing Chen[1], Pingsheng Chen[2*] and Ming Ding[1*]

Table 1 Patient characteristics

	n = 245
Sex	
Male (%)	149 (60.81%)
Female (%)	96 (39.18%)
Age (years, Mean ± SD, range)	61.59 ± 11.85 (26–86)
Lymph node size(cm) (Mean ± SD, range)	2.27 ± 0.69 (0.8–4.7)
TBNA passes (Mean ± SD, range)	4.54 ± 1.02 (3–6)

cm, centimeter; SD, standard deviation; TBNA, transbronchial needle aspiration

Table 2 Final pathological results

TBNA Pathology (n = 245)	Number (%)
Malignant	147
Adenocarcinoma	73 (49.66)
Small cell carcinoma*	26 (17.69)
Squamous cell carcinoma	23 (15.66)
Undifferentiated/poorly differentiated carcinoma	18 (12.24)
Metastasis of breast cancer	2 (1.38)
Sarcoma	1 (0.69)
Diffuse large B-cell lymphoma	1 (0.69)
Multiple myeloma	1 (0.69)
Thymoma, type B3	1 (0.69)
Adenoid cystic carcinoma	1 (0.69)
Benign	99
Sarcoidosis	36 (36.36)
No abnormality identified	35 (35.35)
Inflammation	16 (16.16)
Tuberculosis*	8 (8.08)
Pneumoconiosis	3 (3.03)
Actinomycotes	1 (1.01)

TBNA, transbronchial needle aspiration

*One patient was diagnosed with small cell carcinoma comorbid with tuberculosis

Table 3 Diagnostic performance of EBUS elastography, ROSE and combination

Group	Sensitivity (%)	Specificity (%)	PPV (%)	NPV (%)	+LR	−LR	AUC	Youden index
EBUS elastography	90.65	57.63	71.60	84.00	2.14	0.16	0.776	0.4827
ROSE	95.73	79.05	87.70	92.20	4.57	0.05	0.875	0.7478
Combination Group	85.84	92.65	95.10	79.70	11.67	0.15	0.940	0.7849

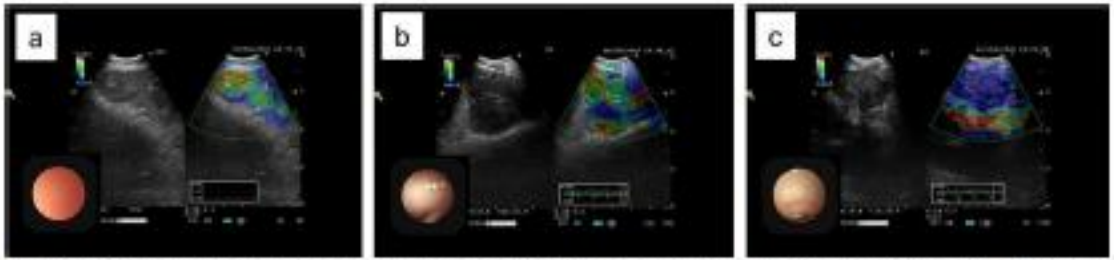

Fig. 1 Representative lymph node status by EBUS elastography image analysis. **a** Type 1, predominantly nonblue (green, yellow, or red); **b** Type 2, partially blue, partially nonblue (green, yellow, or red); **c** Type 3, predominantly blue

Table 3 Diagnostic performance of EBUS elastography, ROSE and combination

Group	Sensitivity (%)	Specificity (%)	PPV (%)	NPV (%)	+LR	−LR	AUC	Youden Index
EBUS elastography	90.65	57.63	71.60	84.00	2.14	0.16	0.776	0.4827
ROSE	95.73	79.05	87.70	92.20	4.57	0.05	0.875	0.7478
Combination Group	85.84	92.65	95.10	79.70	11.67	0.15	0.940	0.7849

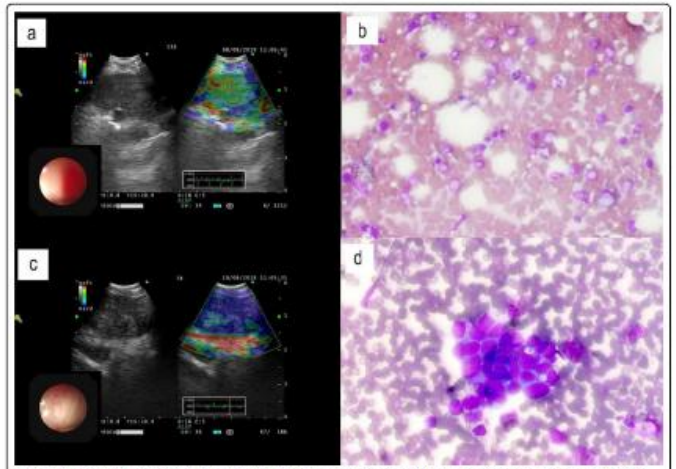

Fig. 2 Representative lymph node status of Types 1 and 3 EBUS elastography images from 2 patients. EBUS elastography image (**a**) and ROSE (**b** Diff-Quik Stain, × 400) of 11R lymph node from a patient with inflammation; EBUS elastography image (**c**) and ROSE (**d** Diff-Quik Stain, × 400) of 7# lymph node from a patient with small cell carcinoma

10cm
W 1200 | T 6,32 SUV-b

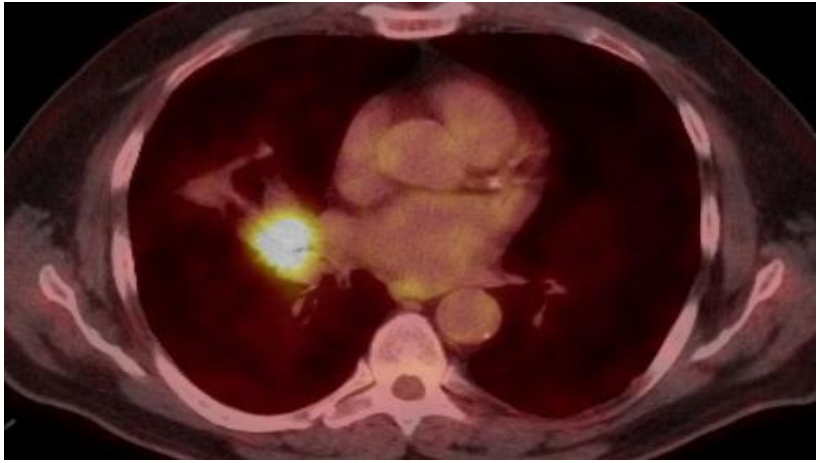

IM 1.0 ITS 0.5 Ann 100% 19 FPS
ICd-10.0H-
D:3.50
GB:78
DB:68

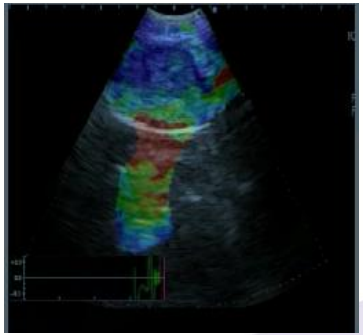

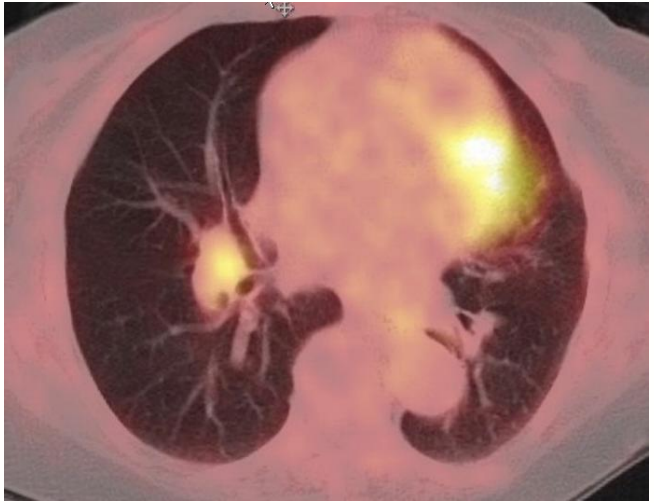

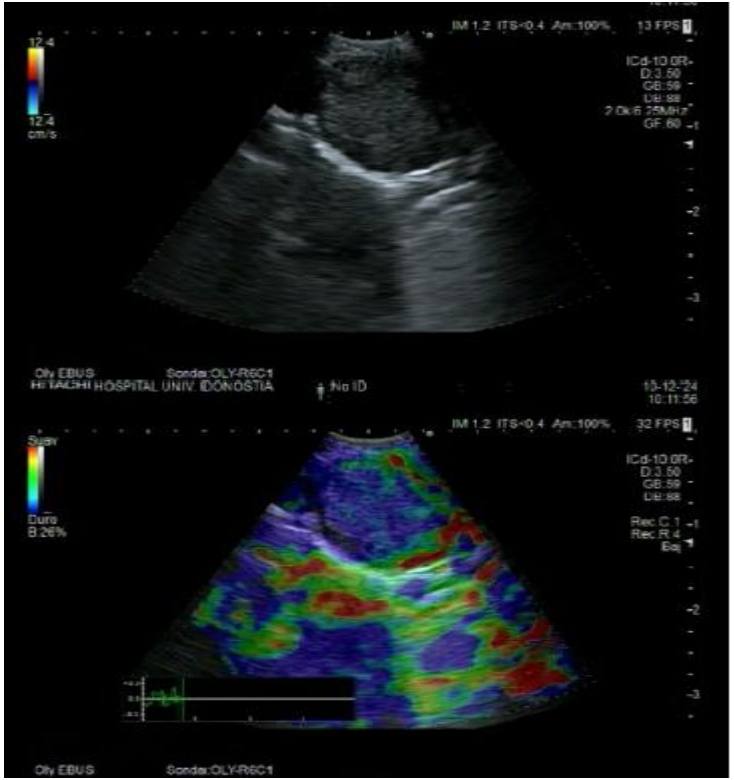
IM 1.2 ITS<0.4 Am:100%
13 FPS
12.4
12.4
cm/s
Oly EBUS
Sonda:OLY-R6C1
HITACHI HOSPITAL UNIV. DONOSTIA
No ID
15-12-'24
10:11:56
IM 1.2 ITS<0.4 Am:100%
32 FPS
Suav
Duro
B 26%
Oly EBUS
Sonda:OLY-R6C1

AÑO 2010

AÑO 2025

CITOLOGÍA:

La **citología** es una ciencia que según su etimología («Cito»: proveniente del griego que significa célula) estudia la célula y todo lo relacionado con su estructura, sus funciones con el microscopio y su importancia en la complejidad de los seres vivos.

BIOPSIA:

Es un procedimiento que extrae células o tejidos de su cuerpo. Un médico llamado patólogo examina las células o tejidos bajo un microscopio para verificar si hay daños o enfermedad. El patólogo también puede hacer otras pruebas a estas células. Las biopsias pueden tomarse de cualquier parte del cuerpo.

Diagnostic yield of EBUS-TBNA for lymphoma and review of the literature

Onur Fevzi Erer, Serhat Erol, Ceyda Anar, Zekiye Aydoğdu[1], Serir Aktoğu Özkan
Departments of Chest Diseases and [1]Pathology, İzmir Dr. Suat Seren Chest Diseases and Surgery Training Hospital, İzmir, Turkey

In conclusion, we believe that since the publication of the BTS guidelines,[9] the value of EBUS-TBNA in the diagnosis of lymphoma still remains controversial. EBUSTBNA can be the first diagnostic modality in diagnosis of recurrent lymphomas. However, for suspected new cases, especially for HL, the diagnostic yield of EBUS-TBNA is low and negative results do not exclude lymphoma. Further interventions such as mediastinoscopy should be performed for high-suspicion patients.

Diagnostic yield of EBUS-TBNA for lymphoma and review of the literature.
Endosc Ultrasound 2017;6:317-22.

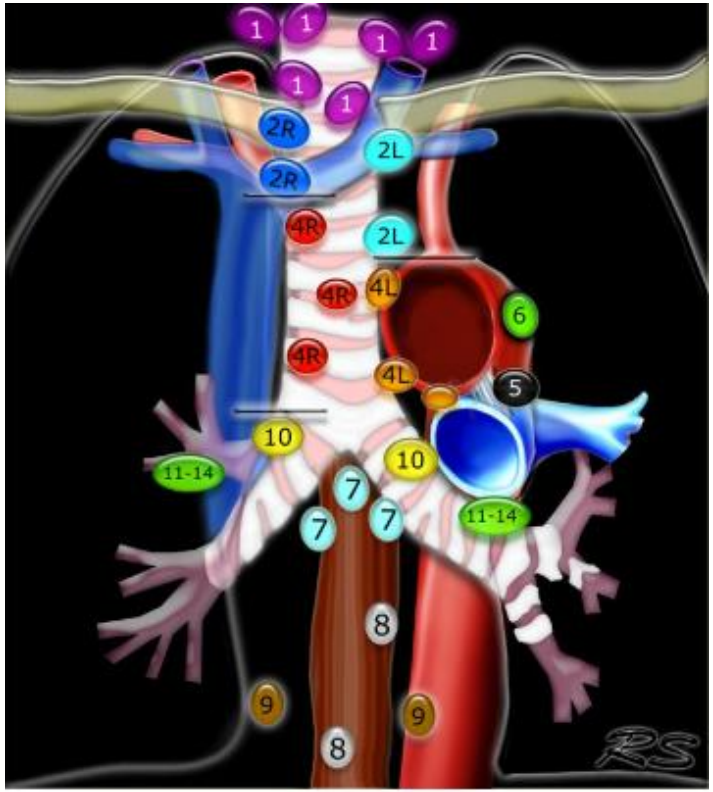

- Toda lesión que esté cerca del árbol traqueo-bronquial proximal y el esófago se pueden obtener muestras:
  - Muestras citológicas (EBUS-TBNA o EUS-B).
  - Muestras Histológicas (CRIOEBUS LINEAL).
- CRIOEBUS LINEAL.
- CRIOEBUS RADIAL.

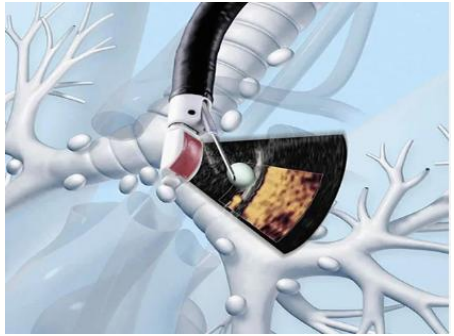

EBUS-TBNA

CRIOEBUS LINEAL

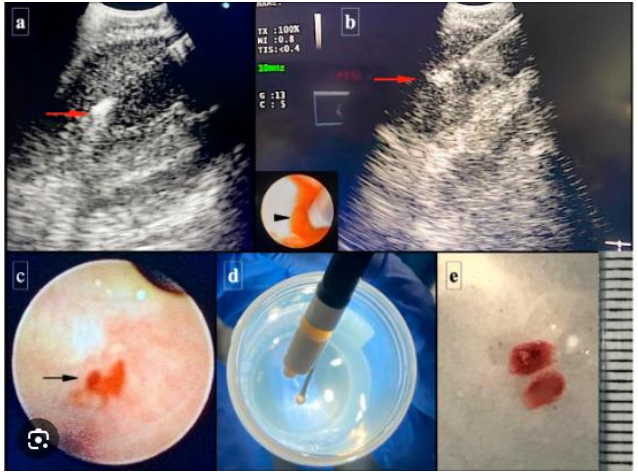

Mediastinoscopia

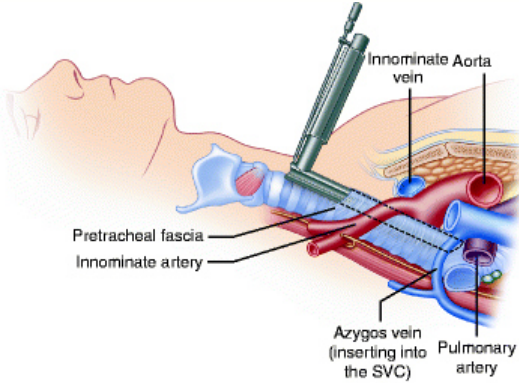

ERJ OPEN RESEARCH
ORIGINAL RESEARCH ARTICLE
M. ARIZA-PROTA ET AL.

Endobronchial ultrasound-guided transbronchial mediastinal cryobiopsy in the diagnosis of mediastinal lesions: safety, feasibility and diagnostic yield – experience in 50 cases

Miguel Ariza-Prota [1], Javier Pérez-Pallarés [2], Alejandro Fernández-Fernández [1], Lucía García-Alfonso [1], Juan A. Cascón [1], Héctor Torres-Rivas [3], Luis Fernández-Fernández [3], Inmaculada Sánchez [4], Maria Gil [4], Marta García-Clemente [1] and Francisco López-González [1]

[1]Division of Respiratory Medicine, Hospital Universitario Central de Asturias, Oviedo, Spain. [2]Division of Respiratory Medicine, Hospital Universitario Santa Lucía, Cartagena, Spain. [3]Division of Pathology, Hospital Universitario Central de Asturias, Oviedo, Spain. [4]Division of Nursery, Hospital Universitario Central de Asturias, Oviedo, Spain.

Corresponding author: Miguel Ariza-Prota (arizamiguel@hotmail.com)

ERJ Open Res 2023; 9: 00448-2022

* Estudio prospectivo (HUCA y Hospital La Vega).
* Enero-agosto 2022.
* Evaluar rendimiento diagnostico , factibilidad y seguridad de EBUS-TMC (CRIOEBUS-LINEAL).
* Todos los procedimientos fueron realizados por 2 broncoscopistas en cada centro.

Criterios de inclusión:

Lesiones mediastinicas >1cm.

EBUS-TBNA y CRIOEBUS-LINEAL.

ROSE no se realizó en todos los pacientes.

Criterios de exclusión:

Pacientes con trastornos de la coagulación.

Fallo respiratorio severo.

Enfermedades cardiacas en fase inestable.

Hipertensión pulmonar.

* En todos los pacientes se utilizó sedación conciente (midazolam y fentanilo)

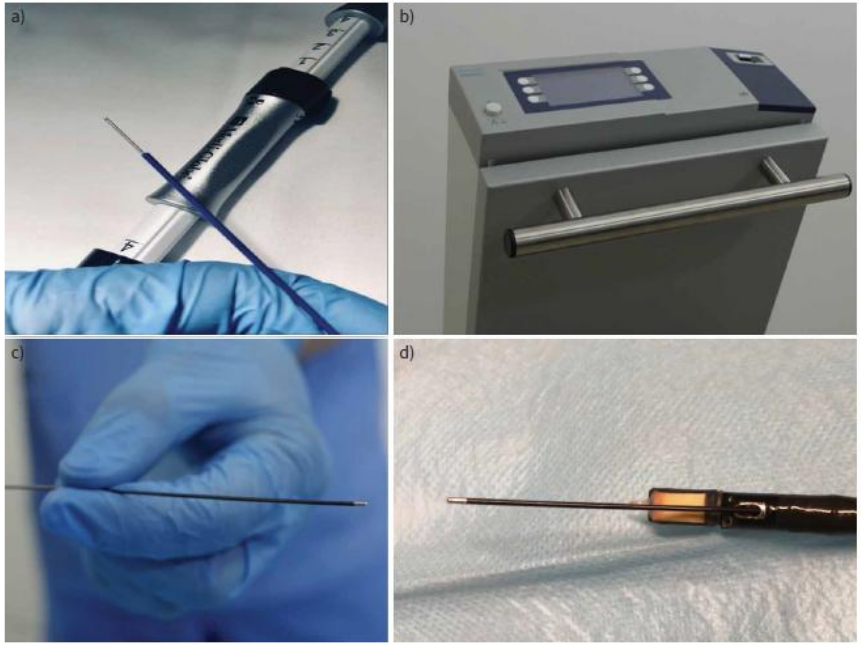

FIGURE 1 a) 22-G needle (SonoTip TopGain: three-point needle tip design with a crown cut). b) ERBECRYO 2 system. c) 1.1-mm cryoprobe (Erbecryo 20402-401). d) 1.1-mm cryoprobe through the working channel of the endobronchial ultrasound bronchoscope (EB19-J10U).

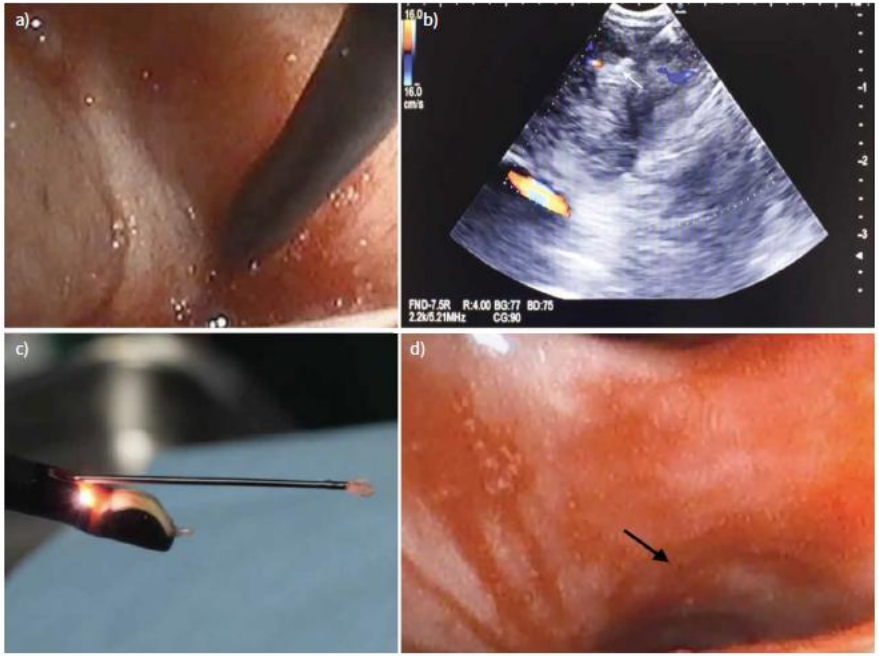

FIGURE 3 a) Tip of the cryoprobe approaching the puncture site. b) Endobronchial ultrasound-Doppler image showing the tip of the 1.1-mm cryoprobe within the lymph node (white arrow). c) Cryobiopsy sample attached to the tip of the probe. d) No bleeding observed after the cryobiopsy (black arrow).

TABLE 2 Endobronchial ultrasound-guided transbronchial needle aspiration (EBUS-TBNA) and transbronchial mediastinal cryobiopsy (TMC) diagnostic yields

	EBUS-TBNA	EBUS-TMC
Diagnosis		
Insufficient	9 (18)	2 (4)
Nonmalignancy	10 (20)	6 (12)
Sarcoidosis	6 (12)	6 (12)
Lung adenocarcinoma	7 (14)	12 (24)
Squamous cell lung carcinoma	4 (8)	8 (16)
Small cell lung carcinoma	6 (12)	6 (12)
Breast carcinoma	1 (2)	1 (2)
Carcinoma of unknown origin	3 (6)	0 (0)
Nonsmall cell lung carcinoma	2 (4)	0 (0)
Not classified lymphoma	2 (4)	0 (0)
Prostate carcinoma	0 (0)	1 (2)
B-cell non-Hodgkin lymphoma	0 (0)	4 (8)
Anthracosis	0 (0)	4 (8)
Diagnoses by pathologies		
Lung cancer	22 (78)	26 (92.9)
Lymphoma	0 (0)	4 (100)
Benign conditions	6 (60)	10 (100)
Diagnostic yield	82	96
Sensitivity	60.7	92.9
Specificity	100	100
Negative predictive value	66.7	91.7
Positive predictive value	100	100
Concordance		
Yes	28 (56)[#]	

Data are presented as n (%) or %. [#]: $p=0.239$, $\kappa=-0.078$.

TABLE 3 Sample size comparison between endobronchial ultrasound-guided transbronchial needle aspiration (EBUS-TBNA) and transbronchial mediastinal cryobiopsy (TMC)

	Sample size (cm)		p-value
	Mean±SD	Minimum–maximum	
TBNA	0.20±0.08	0.10–0.40	<0.001
TMC	0.46±0.13	0.20–0.80	

TABLE 4 Adverse events for endobronchial ultrasound-guided transbronchial needle aspiration (EBUS-TBNA) and transbronchial mediastinal cryobiopsy (TMC)

	EBUS-TBNA	EBUS-TMC
Bleeding		
Mild <10 mL	8	2
Moderate 10–40 mL	2	0
Severe >40 mL	0	0
Pneumothorax	0	0
Pneumomediastinum	0	0
Mediastinitis	0	0
Death	0	0

Data are presented as n.

Rentabilidad diagnostica de 82% (EBUS-TBNA) Vs. 96% (CRIOEBUS LINEAL).

No es necesario utilizar electro-bisturí de alta frecuencia.

Obtención de muestras mas grandes y mejor conservadas.

Evitaron repeticiones de EBUS-TBNA y mediastinoscopia.

12 pacientes fueron diagnosticados de sarcoidosis (concordancia 100% EBUS-TBNA y CRIOEBUS).

Muestras obtenidas por CRIOEBUS fueron óptimas para un Dx. Definitivo de gran certeza.

Se permitió el Dx. de linfoma en todos los pacientes con alta probabilidad pre-test de linfoma.

Adecuado material para realizar sub-clasificaciones.

Mejor calidad y cantidad de la muestra para realizar NGS y drivers oncogénicos.

6 casos de ADK pulmonar y 4 casos Ca. Escamoso que se obtuvo dx. con CRIOEBUS (reportaron muestra insuficiente en EBUS-TBNA).

2 pacientes reportaron diagnostico insuficiente por CRIOEBUS. Se diagnosticaron por EBUS-TBNA (ADK).

CRIO-EBUS LINEAL (EBUS-TMC):

* Es una técnica mínimamente invasiva.
* Segura y factible.
* Se realiza en la sala de broncoscopias.
* Se puede realizar bajo sedación moderada.
* Debe ser realizado por broncoscopistas intervencionistas con elevada experiencia en realización de EBUS-TBNA.
* Rendimiento Dx. mas elevado que EBUS-TBNA.
* Diagnostico de:
    * Linfoma.
    * Tumores de origen no pulmonar.
    * Cuando se necesite mas muestras en CPNCP para realizar estudio molecular.

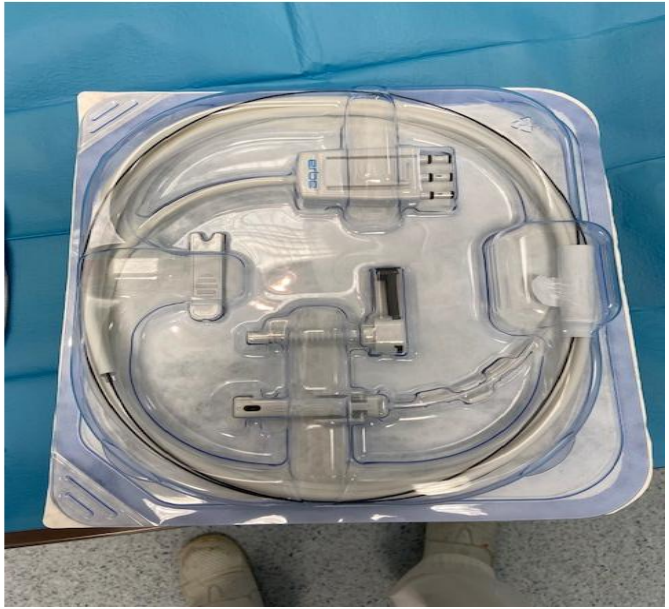

22G
SonoTip TopGain® EBUS
1 Unit
Medi-Globe
Caution!
Caution!
CONNECTIVITY

PAT
PEND
Simport



More than just a better way to guide devices to the target site, the Guide Sheath Kit 2 facilitates a smoother, more efficient approach to peripheral pulmonary lesions, enabling ultrasound identification of the lesion and repeated sampling. Now with a bend-resistant sheath and clip-type device stoppers, this kit provides optimized support for endobronchial diagnosis.

CRIOEBUS RADIAL

* Se basa en la misma técnica del EBUS RADIAL pero con criosonda de 1,1mm o 1,7mm.
* Se obtienen muestras mas grandes.
* Mejor conservadas.

BRONCOSCOPIA TERAPEUTICA

* Curamos a pocos.
* Aliviamos a muchos pacientes.
* Remitir a los pacientes en fases precoces.

Criorrecanalización de un tumor exofítico

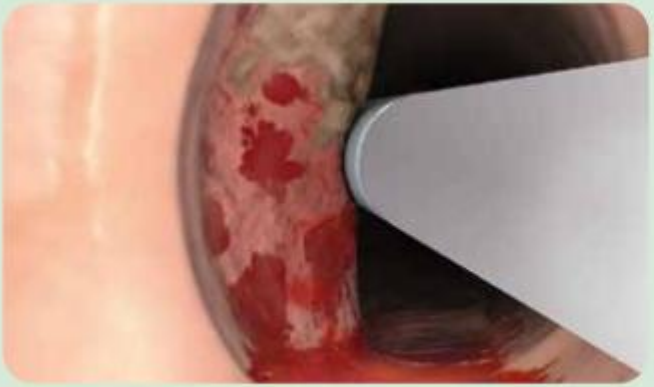

Coagulación

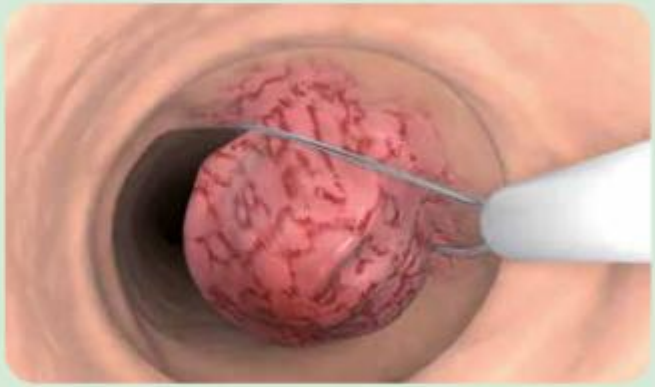

Corte

Aplicaciones de APC

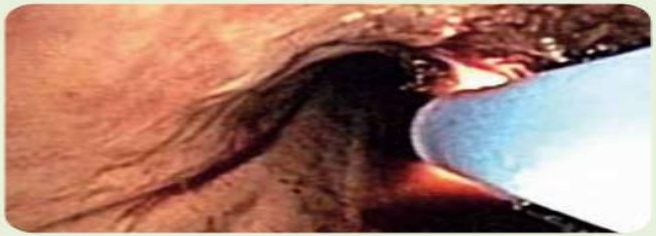

Hemostasia

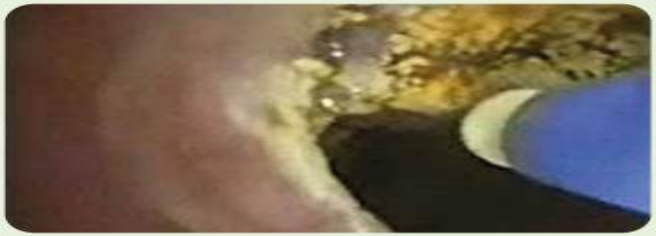

Recanalización

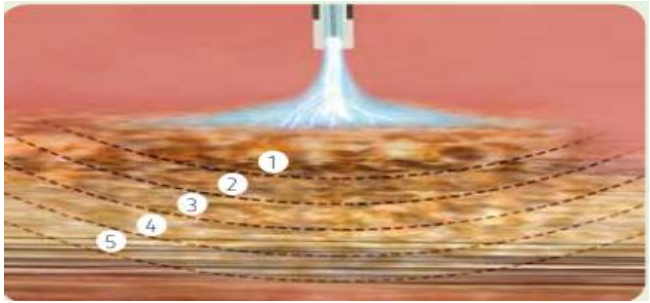

NAVEGACIÓN ELECTROMAGNETICA:

- Guiar instrumentos endoscópicos hacia lesiones pulmonares.
- Utilizando un sistema de seguimiento electromagnético.
- Utilizando imágenes previas de TAC.
- No requiere bronquio de drenaje.

Combinación de técnicas de simulación y navegación electromagnética endoscópica

Combination of Simulation Techniques and Endoscopic Electromagnetic Navigation

David Rincón García[a,*] y Andrés Giménez Velando[b]

[a] *Departamento de Cirugía Torácica, Fundación Jiménez Díaz, Madrid, España*
[b] *Servicio de Neumología, Fundación Jiménez Díaz, Madrid, España*

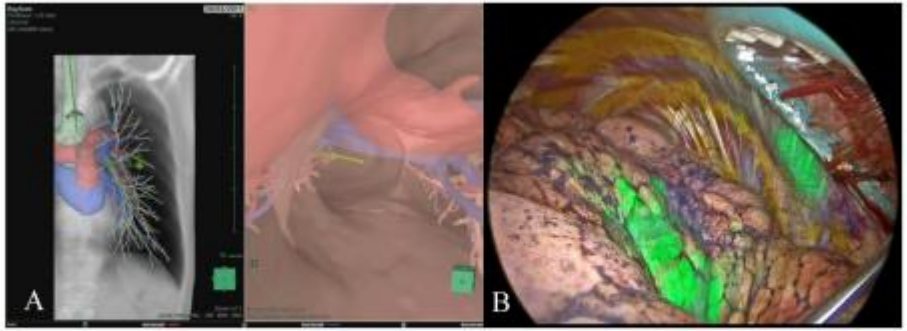

Figura 1. Localización y marcación de nódulo pulmonar a través de navegador electromagnético. A) Reconstrucción de la anatomía bronquial y navegación electromagnética para localizar nódulo pulmonar. B) Visualización de nódulo pulmonar marcado con verde de indocianina.

Open Respiratory Archives 6 (2024) 100381

CONCLUSIONES

- Todo lo que esté cercano al árbol traqueo-bronquial proximal y esófago es accesible por EBUS/EUS-B y se pueden obtener muestras.
- La 9ª edición TNM nos va a generar procedimientos mas largos.
- Una correcta estadificación mediastinica minimizará el riesgo de recidiva ganglionar.
- CrioEBUS lineal y CrioEUS lineal es una técnica novedosa para obtener muestras de biopsia de ganglios y masas pulmonares.
- CrioEBUS radial reporta muestras mas grandes y mejor conservadas que el EBUS radial.
- Remitir a los pacientes de forma precoz cuando se requiera alguna técnica desostructiva terapéutica.

MUCHAS GRACIAS

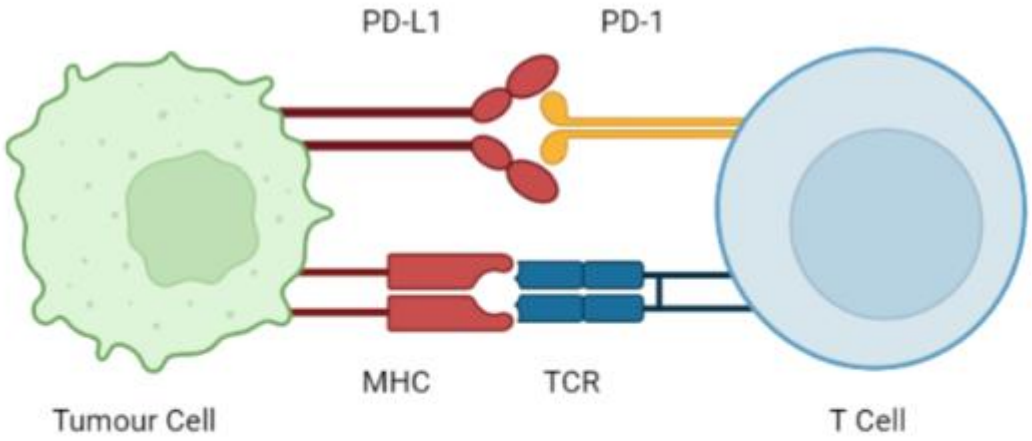

PD-1 & PD-L1 interaction between T-cells and tumour cells.